



RESENTING CLINICAL SIGNS

History: Previously diagnosed with mild DTVD. History of bronchopneumonia and elevated BNP (1651) in July 2019, 1397 in March 2021. No murmur. Slowing down. Sedated for exam with acepromazine and butorphanol.

DATE

5/17/22

ECHOCARDIOGRAPHIC FINDINGS

PERFORMED BY:

2D, M-mode, and Doppler study. This exam is compared to the one performed 10/19/21.

Dr. Brian Barnes

Left atrial size is normal. The mitral valve appears normal, though trace mitral regurgitation is present. Left ventricular dimensions are normal, as is left ventricular systolic function. The aorta and aortic valve appear normal, though trivial aortic insufficiency is present. Right atrial and right ventricular dimensions are normal. The tricuspid leaflets are mildly thickened, and a mild jet of tricuspid regurgitation is present. TR velocity does not suggest the presence of pulmonary hypertension. The pulmonary artery and pulmonic valve appear normal, though trace pulmonic insufficiency is present. No pericardial effusion or cardiac masses are seen.

INTERPRETED BY

Keith Blass, DVM,
MS, DACVIM
(Cardiology)

ECG during echo: Sinus arrhythmia

PATIENT

Anou Landry

LA - 43.3 mm (prev. 46.7 mm)
LVIDd - 37.3 mm (prev. 41.6 mm)
LVIDs - 26.4 mm (prev. 29.7 mm)
FS - 29.4% (prev. 28.6%)
LVOT - 1.43 m/s (prev. 1.44 m/s)
RVOT - 0.86 m/s (prev. 0.90 m/s)
TR - 1.6 m/s (prev. 2.20 m/s)

SPECIES

Canine

ASSESSMENT/RECOMMENDATIONS

Degenerative tricuspid valve disease

BREED

Golden Doodle

This examination demonstrates no progression of Anou's tricuspid valve disease over the past 7 months. As such, his tricuspid valve disease still appears to be well-compensated, and Anou's current risk for the development of clinical signs secondary to his disease still appears to be low.

SEX

No therapy is recommended at this time.

MN

A recheck echocardiogram is recommended in 9 months, sooner if clinical signs compatible with cardiac dysfunction develop.

AGE

13 y

WEIGHT

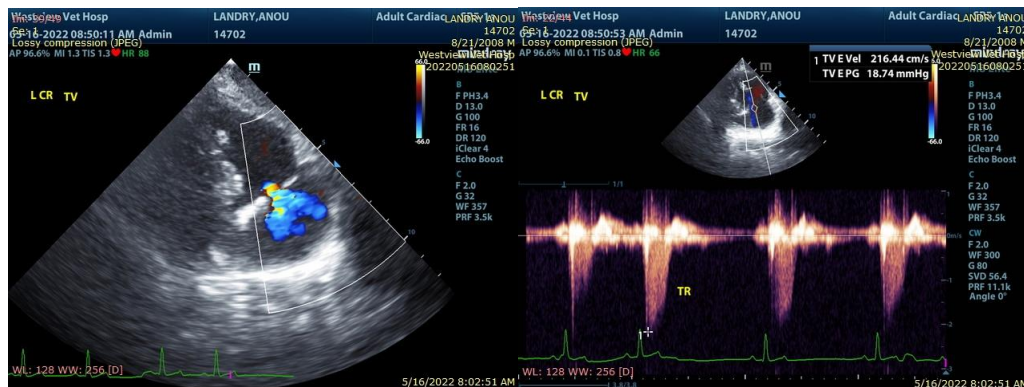
37.5 kg

HOSPITAL NAME

Westview VH

REFERRING VET

Dr. Barnes





The information and recommendations provided are based on the images presented by the referring veterinarian. No evaluation can be communicated regarding pathology that was not visible in the image/video clips provided.

DATE

5/17/22

Thank you for this referral. If the clinical or image interpretation does not parallel your findings or if I can be of any further assistance please contact me.

PERFORMED BY:

Keith Blass, DVM, MS, DACVIM (Cardiology)
KeithBlass@gmail.com
631-804-5754

Dr. Brian Barnes

INTERPRETED BY

Keith Blass, DVM,
MS, DACVIM
(Cardiology)

PATIENT

Anou Landry

SPECIES

Canine

BREED

Golden Doodle

SEX

MN

AGE

13 y

WEIGHT

37.5 kg

HOSPITAL NAME

Westview VH

REFERRING VET

Dr. Barnes